CASE REPORT

Off Pump Total Arterial Coronary Revascularization in Dextrocardia with Situs InversusTotalis: A Case Report

Hemlata Verma*, Anula Sisodia*, R M Mathur, Himanshu Mahala*, Vaibhav Gupta***, Deva Ram Chaudhary***, Harnish Singh Bhatia*****

ABSTRACT

Dextrocardia with situs inversus is a rare entity and if not associated with any congenital heart disorder then these persons lead a normal life. CABG in dextrocardia is technically a challenging task. Here we are reporting a case of off pump total arterial CABG in a patient with dextrocardia with situs inversustotalis with regard to technique and modifications for the surgery.

Key words: dextrocardia, situs inversustotalis, CABG, off pump, congenital, heart.

INTRODUCTION

Dextrocardia is usually associated with congenital heart diseases and if not, then, it behaves normally like levocardia with regard to natural history. Dextrocardia with situs inversus behaves more like normal than dextrocardia with situs solitus.

Coronary artery disease after age 40 year is very common in normal levocardia heart (i.e. apex of heart is on left side with atrial situs and main mass of heart is lying left of the midline) although may occur in younger age group. Dextrocardia is not exception for this yet an uncommon entity.

Dextrocardia is associated with surgical challenges eg, position of surgeon, cannulation for CPB, conduit selection, graft configuration, sequence of anastomosis etc.

Here, we are presenting a case of situs inversustotalis with dextrocardia with TVD in which total arterial revascularization was done off pump.

PATIENT PROFILE

59 year old female presented to us with history of recurrent angina right side of chest radiating to right arm for last 3 years and an episode of acute myocardial infarction 3 months back. Coronary angiography was done which showed Tripple vessel disease. She was referred to us for surgery.

She was non hypertensive and, non diabetic with no history of other chronic illness.

Patient was thoroughly evaluated with routine blood investigations, viral markers, and covid test. Her chest x-ray (Picture/illustration 1) showed dextrocardia with situs inversus. Liver was under left hemidiaphragm and fundal shadow was under right hemidiaphragm.

HRCT thorax for covid infection was also negative

Electrocardiography (Figure 2) was typical of dextrocardia and Coronary artery disease i,e. inverted P wave with negative QRS deflection in lead 1 and upright P wave with positive QRS deflection in lead avR and poor progression of R wave in left chest leads.

Findings suggestive of Coronary artery disease were presence of q wave in lead V2, V5, V6, ST depression with T wave inversion in lead V4R, V5R, and V6R.

2D echo (Figure 3) showed situs inversus with dextrocardia with normal chamber dimensions. Superior vena cava and Inferior vena cava were on left side of spine and draining into left side placed Right atrium. Pulmonary veins draining into right sided left atrium. Apex was lying on right side of midline. Morphologic right ventrical was on left side of midline and morphologic left ventricle was on right side of midline. Aorta was lying on right side of spine and ascending aorta was situated on left side of main pulmonary artery with ventriculo arterial concordance. There was grade II left ventricular diastolic dysfunction with normal systolic function (Ejection fraction – 55 %).

*Associate Professor, **Senior Professor, ***Resident Doctor
Department of Cardiothoracic and Vascular Surgery, SMS Medical College & Hospital, Jaipur, Rajasthan
Corresponding author:
Dr. R M Mathur
Senior Professor and Unit Head
CTVS Department, SMS Hospital, Jaipur, Rajasthan
Address: 48, Bajaj Nagar Enclave, Jaipur, Rajasthan (302015)
+91-9829063353
Email : rajendra.mathur@rediffmail.com

Coronary angiography (Figure 4a,4b,4c,4d) revealed mirror image coronary artery pattern with left arterial system was lying on right side of main mass and right coronary artery was on left side of main mass. There was approximately 95% stenosis in proximal Left anterior descending artery, obtuse marginal 1, proximal right coronary and distal right coronary artery just before crux.

Ultrasonography abdomen confirmed the finding of abdominal situs that is liver was on left side and spleen was on right side.

There was moderate to severe obstructive respiratory dysfunction and both carotid arteries were normal on colour Doppler study.

With negative corona profile and HRCT thorax, patient was taken for surgery.

Her both radial arteries were checked with Allen test for harvesting IMA and Radial artery.

INTRA OPERATIVE PROFILE

ECG electrodes were fixed on back side of right chest wall. Patient was anesthetized with fentanyl, sodium thiopental, and rocuronium and maintained with sevoflurane and intermittent doses of fentanyl and rocuronium. Arterial and venous monitoring lines were placed and urinary catheterization was done.

Chest was opened with midline sternotomy, pericardium was opened and hitched up. Anatomy (Figure 5) of heart was consistent with mirror image pattern with right aortic arch. LAD was situated on right side, OM was on right lateral surface, RCA was on left side, and PDA was situated on inferior wall left side.

After inspection of anatomy, RIMA (Figure 6a,6b,6c), LIMA (Figure 6d,6e), and LEFT RADIAL (Figure 6f) artery were harvested on 1 mg/kg heparin dose with ACT more than 280 seconds. RIMA was used as pedicled graft and LIMA and RADIAL aretery were used as free graft. Patient was heparinized again to achieve ACT more than 300 seconds. Procedure was done off pump and with surgeon standing on right side of the patient. Proximal anastomosis (Figure 7) were done first with LIMA was anastomosed to right lateral surface and RADIAL artery was anastomosed to left anterolateral surface of ascending aorta with 7/0 prolene in continuous manner. Patency was checked.

Stabilizer was fixed on inferior arm of retractor and LAD (Figure 8) was stabilized. Exposure was improved with hitching up the pericardial stay taken in between the right superior and inferior pulmonary vein. A 5/0 prolene control sling was taken around LAD proximal to the proposed site of anastomosis. Adequate sized LAD arteriotomy was done and shunt of 1.75mm size was placed inside the arteriotomy. RIMA was anastomosed to LAD as pedicled graft with 7/0 prolene in tension free manner. RIMA graft was fixed to epicardium. Now stabilizer was fixed on inferior arm of retractor near its right arm and OM1 artery (Figure 9) was fixed. LIMA was anastomosed to OM1 in similar manner as LAD grafting. For PDA exposure, octopus was stabilized at right arm of retractor near its inferior portion and RADIAL artery was anastomosed to PDA (Figure 10) similarly. Shunt size for OM1 and PDA was 1.5mm.

After completion of the procedure heparin was reversed. Hemodynamically patient's parameters were remain stable throughout the procedure therefore no inotropes were required. Chest was closed in usual manner after inserting bilateral pleural and mediastinal drains. She was shifted to ICU on nitroglycerine infusion.

Postoperative course was uneventful and she was extubated in 6 hrs. Patient was discharged on day 7.

DISCUSSION

Dextrocardia with situs inverses is an unusual congenital abnormality with an incidence of 1: 12,000 [1].

It is subjected to coronary artery disease as in normal population with levocardia and situs solitus[2].

Literature shows that dextrocardia was first reported by anatomist surgeon Hieronymus Fabricius in 1606[3], and Marco Aurelia Severinus in 1643 reported dextrocardia with situs inversus[4]. In adults, mostly it is dextrocardia with atrial and abdominal situs inversus and this is rarely associated with congenital cardiac anomalies.

CABG was first done in dextocardia in 1980[5].

Performing surgery when standing on right side of patient in dextrocardia is technically difficult and doing it off pump is like a pimple has grown upon an ulcer. Some issues have to be sorted out during surgery like where should surgeon stand, doing it off pump or on pump, cannulation strategies, conduits for LAD, OM, PDA, which coronary artery is to be anastomosed first or sequence of anastomosis, position of stabilizer etc.

Selection of conduit and configuration of graft is very important in CABG and it becomes very crucial in dextrocardia because now main mass of heart is on right side. RIMA can easily reach upto LAD in this situation; however Kuwata[6] and chakravarthy[7] used skeletonised LIMA in situ for LAD.

In most of the case reports and paper presented so far it was shown that one arterial graft, which is usually RIMA for LAD was used and for the rest of coronaries venous grafts were used. Kuwata T et al reported a case where he performed total arterial surgery off pump[6]. We decided to do a total arterial revascularization off pump. RIMA was used as pedicled graft for LAD, and LIMA and RADIAL artery conduits were used as free grafts for OM and PDA. Pancelet did total arterial revascularization with the help of cardiopulmonary bypass[8].

Usually RIMA is anastomosed to LAD, considering its proximity to rightward LAD.

In dextrocardia, obtuse marginal vessels are more anterior and a conduit with short length can be used, therefore it is more suitable to do total arterial revascularization as they are less prone to kinking than SVGs [9].

Because of position of the heart in dextrocardia it is preferred to stand on left side of the patient for the coronary anastomosis as it is easy to graft LAD and OM exposed by retracting the heart to left. Few cases are reported in which surgery was done when standing on right side[10] and we found that this surgery can be done with standing on right side without any difficulty.

Texas study showed that in dextrocardia, most surgeons were on the left side, cardiopulmonary bypass was used frequently, and usually one arterial and rest were venous grafts were used[11].

When using cardiopulmonary bypass position of aortic arch is very important to place the arterial cannula and usually in dextrocardia it is right aortic arch[12]. Presence of SVC draining into coronary sinus has to be checked for venous cannulation and retrograde cardioplegia[13].

SUMMARY

Dextrocardia poses challenges to surgeons but slight modifications make the grafting easier. Although in our case we did not change the surgeon's position and completed the whole procedure as we do CABG in levocardia without any difficulty. By doing total arterial revascularization without the help of cardiopulmonary bypass we could do the best for the patient in our scenario.

REFERENCES

1. Bohun CM, Potts JE, Casey BM, et al. A population – based study of cardiac malformations and outcomes associated with dextrocardia. *Am J Cardiol*2007;2013:305-9.
2. Hynes HM, Gau GT, Titus JL. Coronary heart disease in situs inversustotalis. *Am J Cardiol*. 1973;31:666 – 9.
3. Cleveland M. Situs inversusviscerum : Anatomic study. *Arch Surg.*1926;13:343.
4. Brown JW. Congenital Heart Disease. London: *Staples Press* Ltd;1950.
5. Irvin RG, Ballenger JF. Coronary artery bypasses surgery in a patient with situs inversus. *Chest.*1982;81:380- 1.
6. Kuwata T, Kawata T, Ueda T, Sakaguchi H, Nagasaka S, Taniguchi S. Off pump quintuple coronary artery bypass grafting for situs inversustotalis. *Jpn J ThoracCardiovascSurg* 2004;52(10):473-5.
7. Chakravarthy M, Jawali V, Nijagal D. Off- pump coronary artery bypass surgery in dextrocardia : a report of two cases. *Ann ThoracCardiovascSurg* 2008;14(3):187- 91.
8. Pancelet AJ, Dion R, Lengele B, Nairhomme P. Complete arterial revascularization in coronary artery bypass grafting in patients with situs inversustotalis. *J CardiovascSurg (Torino)* 2006;47(4):477 – 9.
9. Naik MJ, Chua YL, Ding ZP, Lau KW. Coronary artery bypass grafts in situs inversus. *J CardiovascSurg (Torino)* 2002;43(2):181 – 4.
10. Saad RA, Badr A, Goodwin AT, Dunning J. Should you stand on the left or the right of a patient with dextrocardia who needs coronary surgery? *Interact Cardiovasc Thoracic Surg.*2009;9:698-702.
11. Murtuza B, Gupta P, Goli G, Lall KS. Coronary revascularization in adults with dextrocardia. Surgical implications of anatomic variants. *Tex Heart Inst J.* 2010; 37:633-40.
12. Arcilla RA, Gasul BM. Congenital dextrocardia. Clinical, angiographic, and autopsy studies on 50 patients. *J Pediatr.*1961;58:251-62.
13. Kurisu K, Ochiai Y, Kumeda H, Kimura S, Tanaka K, Tominaga R. Coronary artery bypass grafting with absent right superior vena cava in visceroatrial situs solitus. *Jpn J ThoracCardiovascSurg* 2004;52(4):191-3.

LIST OF ABBREVIATION

CABG	:	Coronary Artery Bypass Grafting
CPB	:	Cardiopulmonary Bypass
CAD	:	Coronary Artery Disease
TVD	:	Triple Vessel Disease
HRCT	:	High Resolution Computerized Tomography
IMA	:	Internal Mammary Artery
RIMA	:	Right Internal Mammary Artery
LIMA	:	Left Internal Mammary Artery
ECG	:	Electrocardiogram
LAD	:	Left Anterior Descending Artery
OM	:	Obtuse Marginal
RCA	:	Right Coronary Artery
PDA	:	Posterior Descending Artery
ICU	:	Intensive Care Unit
SVG	:	Saphenous Vein Graft
SVC	:	Superior Vena Cava

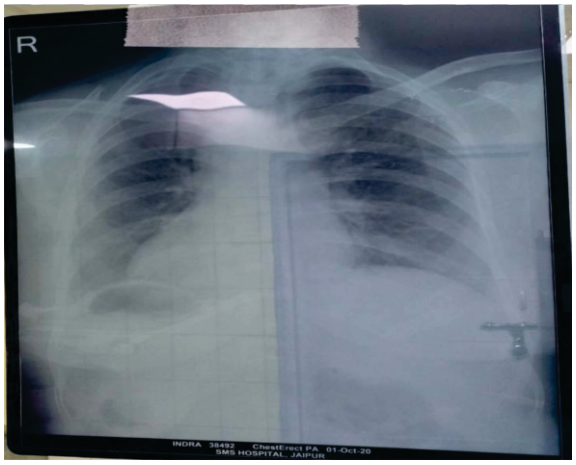

Figure 1: Chest X-ray

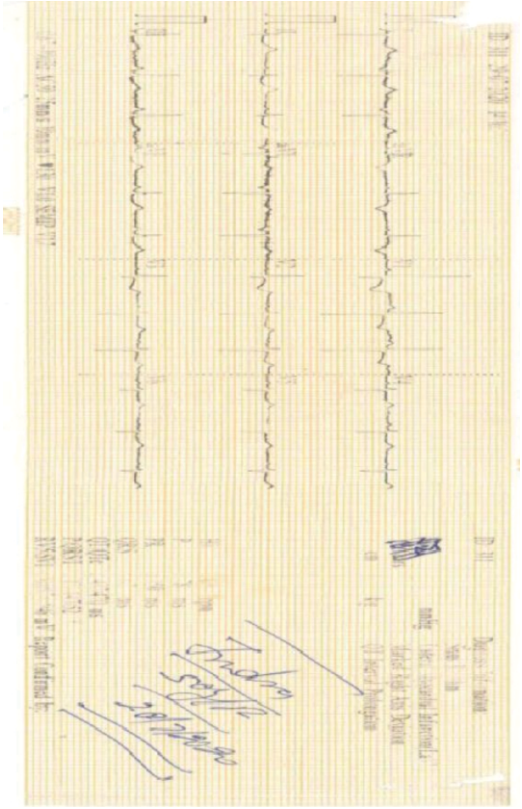

Figure 2: ECG



Figure 3: 2D Echo Report

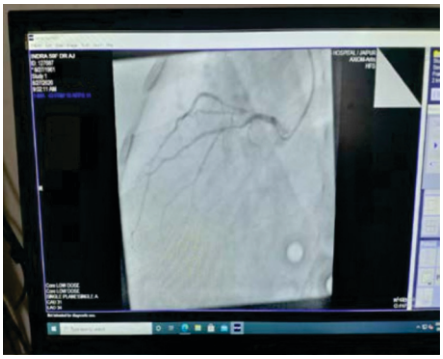

Figure 4a: LAD and Left Circumflex Artery

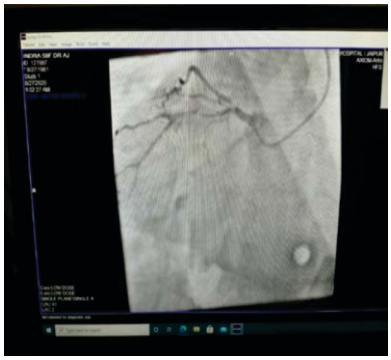

Figure 4b: LAD and Left Circumflex Artery

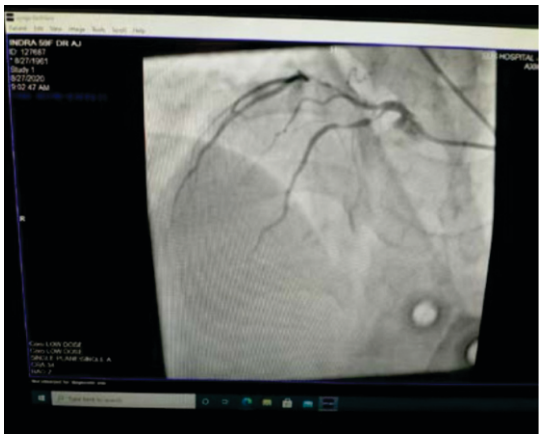

Figure 4c: LAD and Left Circumflex Artery

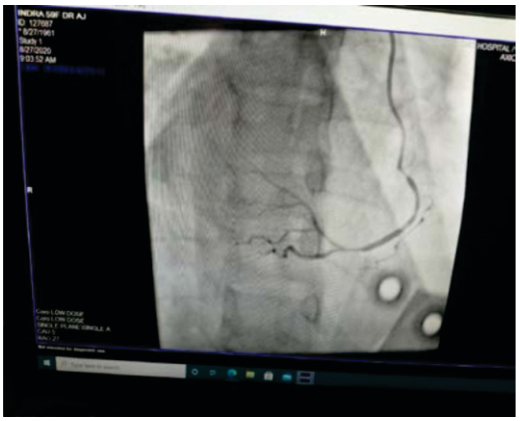

Figure 4d: Right Coronary Artery

Figure 5: Anatomy

Figure 6a: RIMA Harvesting

Figure 6b: RIMA Graft

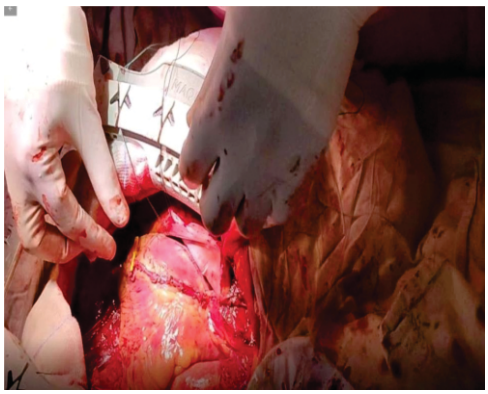

Figure 6c: RIMA Graft

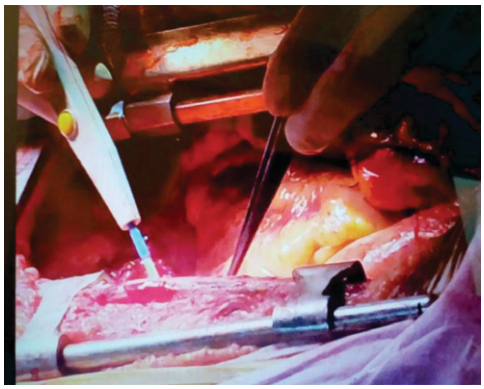

Figure 6d: LIMA Harvesting

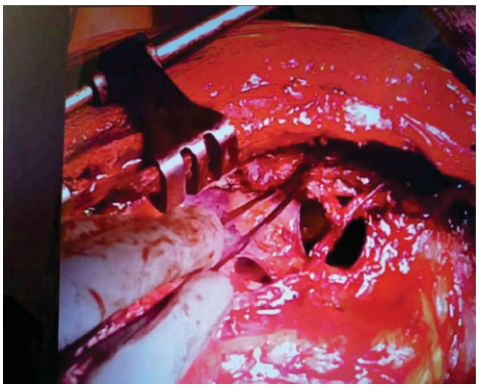

Figure 6e: LIMA

Figure 6f: Left Radial Artery Graft Harvesting

Figure 7: Proximal Anastomosis

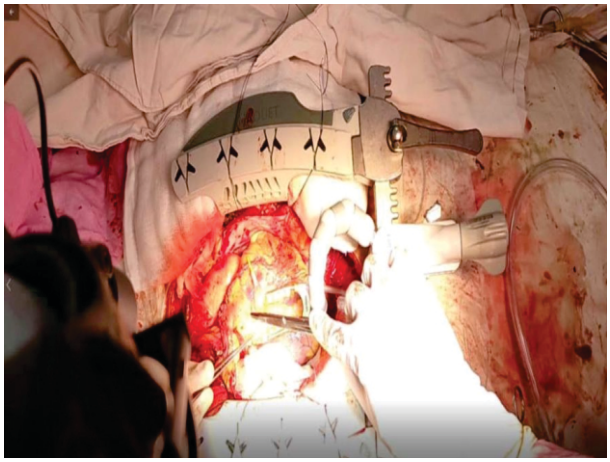

Figure 8: LAD Grafting

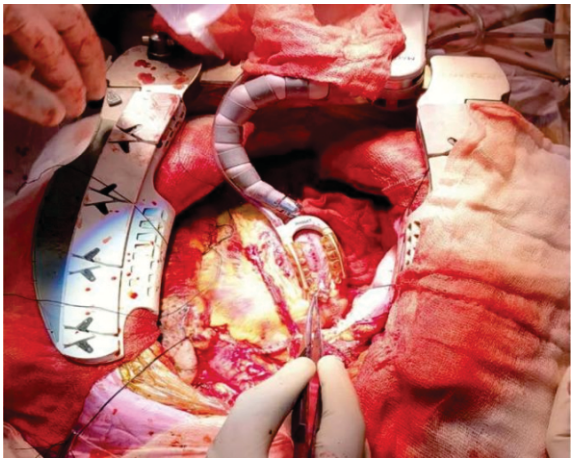

Figure 9: OM 1 Grafting

Figure 10: PDA Grafting